

Oncocytic Lipoadenoma of the Parotid Gland: Report of a Rare Case

CLEMENT WILFRED DEVADOSS, PAARI MURUGAN, DEBDATTA BASU, JAGDISH S.

ABSTRACT

Background: Oncocytic lipoadenoma is a very uncommon, benign, salivary gland tumor. There are only rare case reports of this distinct entity.

Case: A 50-year-old-female patient presented with a slow growing swelling, in the left parotid region which was clinically interpreted as a soft tissue tumor, with a differential of neurofibroma/lipoma. Based on fine needle aspiration cytology (FNAC), a diagnosis of oncocytoma with a remote possibility of an “acinic cell carcinoma with oncocytic features” was suggested. Histopathologic exam-

ination showed it to be an encapsulated tumor with an intimate admixture of mature fat cells and oncocytes. The latter was present in glandular or microacinar pattern. The cells were positive for pancytokeratin and epithelial membrane antigen and negative for smooth muscle actin.

Conclusions: Histopathologists should be aware of an entity called oncocytic lipoadenoma of the salivary gland in order to differentiate it from other oncytic and lipomatous lesions of salivary gland and diagnose it precisely.

Key Words: Gland, Salivary, Parotid, Lipoadenoma, Oncocytic

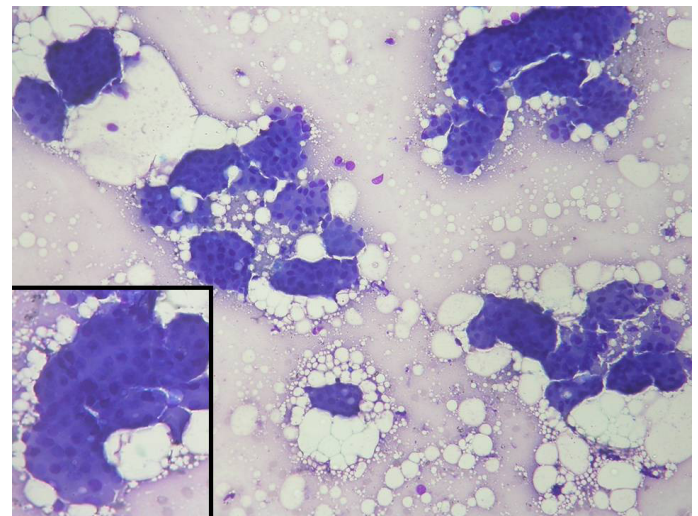
INTRODUCTION

“Oncocytic lipoadenoma” is an extremely uncommon, benign, salivary gland tumour which was first described in 1998 by Hirokawa et al. [1] This tumour has not been included in the 2005 WHO classification of the tumours of the salivary glands [2]. Till date, in addition to the original case, only very few other examples of this particular entity have been documented in the literature [3-6]. In this case report, we have described the clinicopathological and the immunohistochemical features of an additional case of oncocytic lipoadenoma of the parotid gland. In addition, we have discussed the features which differentiate this tumour from other lipomatous and oncocytic lesions of the salivary gland.

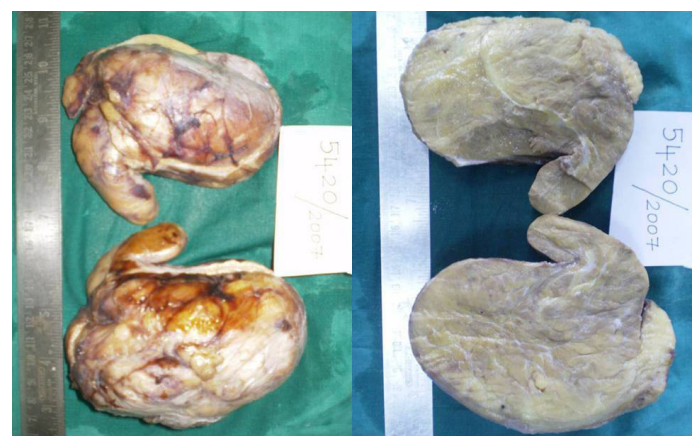
CASE REPORT

Clinical summary: A 50-year-old-female patient presented with a slow growing swelling in the left parotid region, of 6 year's duration. On examination, the swelling was found to be of the size, 14x12x10cm, soft, well-defined and mobile, with no evidence of the involvement of the overlying skin, or the underlying structures. Clinically, a diagnosis of a soft tissue tumour was made, with a differential diagnosis of neurofibroma/lipoma. The patient was referred for a fine needle aspiration cytology, which reported the tumour as an oncocytoma with a remote possibility of it being an oncocytic variant of an acinic cell tumour [Table/Fig-1]. The patient underwent a left superficial parotidectomy. During the surgery, the swelling was found to be distinctly encapsulated and it was found to arise from the superficial lobe of the parotid. The facial nerve was uninvolved and it was preserved.

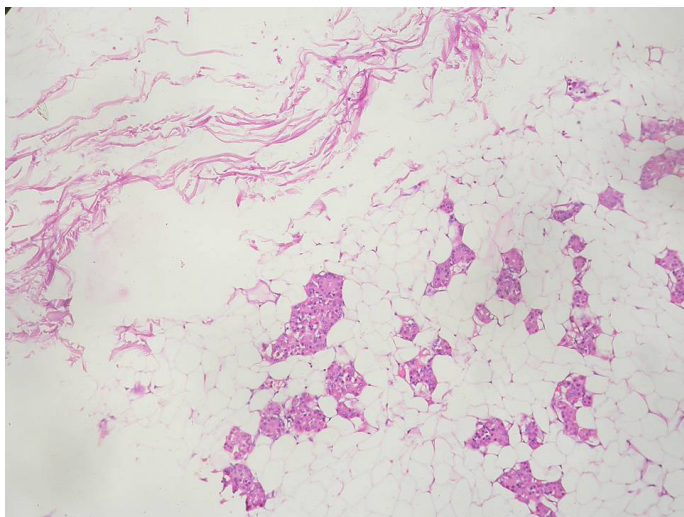
Histopathologic examination: A nodular, soft, ovoid mass which measured 13.5 x 12 x 10.5cm and weighed 490 grams was received in the histopathology laboratory [Table/Fig-2]. The external surface of the mass was thinly capsulated, with a few congested blood vessels. On sectioning, it was found to be clearly capsulated, to



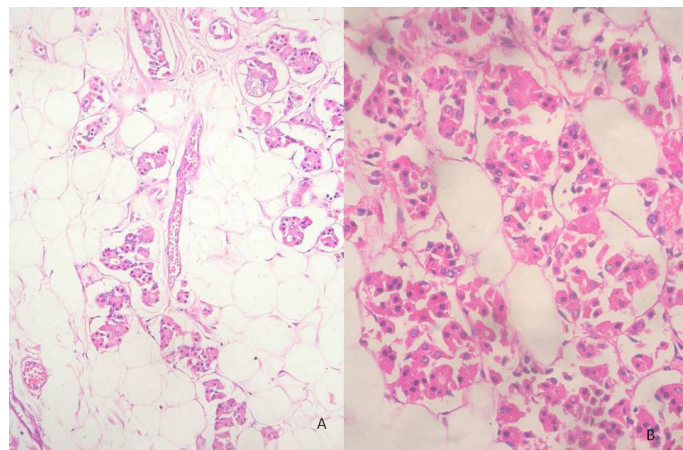
[Table/Fig-1]: Fine needle aspirates showing cohesive sheets and clusters of oncocytes. (MGG, x 400)



[Table/Fig-2]: Nodular, thinly encapsulated mass with grey tan and yellow greasy cut surface.



[Table/Fig-3]: Intimate admixture of fat cells and oncocytic epithelial cells. (H&E, x100)



[Table/Fig-4]: Oncocytic epithelial cells disposed in islands and acinar formations. A (H&E, x100), B (H&E, x400)

be grey tan and yellow and greasy, and it resembled a lipoma. The microscopic examination of the routinely processed histological sections revealed an encapsulated tumour which was composed of an intimate admixture of fat cells and epithelial cells which were evenly distributed throughout the tumour [Table/Fig-3]. The epithelial cells comprised entirely of islands and sheets of oncocytic cells which were arranged in an acinar or a microglandular pattern, with abundant eosinophilic granular cytoplasm and small, centrally placed, round nuclei [Table/Fig-4]. The nucleoli were inconspicuous. No necrosis, atypia or mitotic figures were seen. Approximately 50-60% of the tumour was composed of an abundant adipose tissue which comprised of mature fat cells. Phosphotungstic acid hematoxylin (PTAH) staining demonstrated the presence of diffuse blue cytoplasmic granules in the oncocytes. Immunostaining revealed positivity in the oncocytes for pan cytokeratin and the epithelial membrane antigen. The adipocytes were also positive for vimentin and S100. The epithelial cells were negative for smooth muscle actin.

After having gone through the cases which have been documented in the literature, we arrived at a final histopathological diagnosis of "oncocytic lipoadenoma".

The patient was followed up for 2 years after the surgery, during which there was no recurrence.

DISCUSSION

We have described the morphological features of a rare case of "oncocytic lipoadenoma" of the parotid gland in a middle aged female. Clinically, this tumour presented as a slow growing, huge, mobile mass with a soft consistency, due to which there was a strong clinical suspicion of lipoma/neurofibroma. Even on gross examination, the tumour resembled a lipoma; however, the histopathologic examination revealed it to be an "oncocytic lipoadenoma" which is a distinct morphologic variant of "lipoadenoma" of the salivary gland [1].

Oncocytic lipoadenoma is an extremely rare tumour of the salivary gland that has not been included in the 2005 World Health organization classification of salivary gland tumours [2]. It should be added to the group of oncocytic tumours of salivary gland. Till date, to the best of our knowledge, only few other cases of oncocytic lipoadenoma of the salivary gland have been reported in the English literature [1,3-6]. As in the present case, most of these other cases females and the tumours occurred in the parotid gland.

"Lipoadenoma" of the salivary gland, which was described initially by Yau et al in 1997, is a rare, benign, salivary gland tumour which is characterized by an admixture of epithelial and adipose tissue components [7]. Histologically, the ductal structures appear as elongated tubules which have either small or no lumina. The ducts are lined by columnar cells which are positive for low molecular weight keratin, which are supported by a basal cell layer which is positive for high molecular weight cytokeratin. This basal cell layer lacks myoepithelial differentiation. The tumour is thought to be of striated ductal cell origin [3,7,8]. The term "lipoadenoma" was proposed for these tumours in order to distinguish them from the "adenolipomas" that occur at sites such as the breast, thyroid, and the skin. Adenolipomas which involve the non-salivary gland tissue are considered as either hamartomas, or as variants of lipomas with entrapped glandular elements, in contrast to the "lipoadenomas of the salivary gland" which are true neoplasms [4].

The term "oncocytic lipoadenoma" is used, when the epithelial element consists of oncocytes.¹ It is well known that oncocytes can be seen in a variety of non-neoplastic and neoplastic conditions such as oncocytic metaplasia, nodular or diffuse oncocytic hyperplasia, Warthin's tumour, oncocytoma, and oncocytic carcinoma [1]. Histologically, all these lesions can be differentiated from "oncocytic lipoadenoma". Of these, "oncocytic metaplasia of the acinar or the ductal cells of the salivary glands" does not manifest as a solitary mass. "Nodular oncocytic hyperplasia" is an unencapsulated, non-neoplastic lesion which is usually multiple. "Diffuse oncocytic hyperplasia" is an unencapsulated lesion, and as its name implies, it shows a diffuse involvement of the entire salivary gland.¹ "Warthin's tumour" consists of papillae which are lined by oncocytes which have intense lymphocytic infiltrates, which often form germinal centers in the fibrovascular papillary core. "Oncocytoma" and "oncocytic carcinoma" show neoplastic oncocytes as their exclusive components and they lack the presence of adipose tissue [2].

The rare cases of "sialolipoma" and "pleomorphic adenoma with extensive lipometaplasia" also need to be considered in the differential diagnosis of "lipoadenoma of the salivary gland". Sialolipoma is also a well-circumscribed mass which is composed of glandular tissue and mature fat cells [9]. However, unlike lipoadenoma and its oncocytic variant, the glandular component in sialolipoma consists of ductal, acinar and myoepithelial cells which closely resemble normal salivary gland tissue [9]. Pleomorphic adenomas with extensive lipometaplasia are extremely rare, and these are generally encountered in the minor salivary glands. Sometimes,

the lipometaplasia in these cases may comprise >90% of the total tumour volume [10]. It has been proposed that in these tumours, lipocytes are formed as a result of lipid accumulation in the myoepithelial cells.

The neoplastic oncocytes of "oncocytic lipoadenoma" display abundant, eosinophilic, finely granular cytoplasm, and single, small, round nuclei which have conspicuous nucleoli. A second cell population which is composed of small, densely eosinophilic cells with pyknotic nuclei, which have been referred to as the "dark" cells, have also been described [1]. In the present case, the nucleoli were inconspicuous in the neoplastic oncocytes. Histologically, the oncocytic cells are described as appearing in an acinar, or a microglandular pattern [1], or as small sheets [3]. The PTAH staining is ideal for demonstrating the oncocytic nature of the cells as small dark-blue cytoplasmic granules [5]. Kleib and Perez-Ordóñez reported a case of "oncocytic lipoadenoma" which presented with a sebaceous differentiation [4]. Kato and Horie demonstrated abundant mitochondria in the cytoplasm of the neoplastic cells of "oncocytic lipoadenoma" of the parotid gland, immunohistochemically and ultra-structurally. Based on their findings, they suggested that the glandular elements were derived from the striated ductal cells [3]. The lack of staining of the smooth muscle actin in the cells supports the absence of a myoepithelial cell component in this tumour [4]. Recently, Ilie et al, demonstrated the translocation t(12;14) which resulted in a structural rearrangement in the region which framed the HMGA2 gene at chromosome 12q14.3 in a case of oncocytic lipoadenoma of the parotid gland in a 64-year-old male.[6] Such alterations in HMGA2 have been described in both lipomas and pleomorphic adenomas of the salivary glands.

To conclude, we have documented the histological and the immunophenotypic findings of a rare case of "oncocytic lipoadenoma" of the parotid gland.. An awareness on the part of histopathologists, of the existence of this particular neoplasm is essential for its precise diagnosis.

REFERENCES

- [1] Hirokawa M, Shimizu M, Manabe T Ito J. Oncocytic lipoadenoma of the submandibular salivary gland. *Hum Pathol* 1998; 29: 410-12.
- [2] Barnes L, Eveson JW, Reichart P, Sidransky D eds. The World Health Organisation Classification of Tumors: Pathology and Genetics: Head and Neck Tumors. Lyon, France: IARC Press: 2005;209-81.
- [3] Kato M, Horei Y. Oncocytic lipoadenoma of the parotid gland. *Histopathology* 2000; 36: 285-86.
- [4] Kleib HB, Perez-Ordóñez B. Oncocytic lipoadenoma of the parotid gland with a sebaceous differentiation. A study on its keratin profile. *Virchows Arch* 2006; 449: 722-25.
- [5] Aouad R, Matar N, Sader-Ghorra C, Haddad A. Pathology quiz case 1. Oncocytic lipoadenoma of the parotid gland. *Arch Otolaryngol Head Neck Surg* 2008; 134: 446- 8.
- [6] Ilie M, Hofman V, Pedeutour F, Attias R, Santini J, Hofman P. Oncocytic lipoadenoma of the parotid gland: immunohistochemical and cytogenetic analyses. *Pathol Res Pract*. 2009 Apr 3. [Epub ahead of print].
- [7] Yau KC, Tsang WY, Chan JK. Lipoadenoma of the parotid gland with a probable parotid duct differentiation. *Mod Pathol* 1997;10:242-46.
- [8] Hirokawa M, Bando Y, Tashiro T, Kuma S, Kawata I, Sano T. Parotid lipoadenoma with sclerotic and polycystic changes. *Virchows Arch* 2002; 440:549-50.
- [9] Nagao T, Sugano I, Ishida Y, Asoh A, Munakata S, Yamazaki K, Kanno A, Kondo Y, Nagao K. Sialolipoma: a report of seven cases of a new variant of salivary gland lipoma. *Histopathology* 2001; 38: 30-36.
- [10] Seifert G, Donath K, Schäfer R. Lipomatous pleomorphic adenoma of the parotid gland. Classification of the lipomatous tissue salivary glands. *Pathol Res Pract*.1999;195:247-52.

AUTHOR(S):

1. Dr. Clement Wilfred Devadoss
2. Dr. Paari Murugan
3. Dr. Debdatta Basu
4. Dr. Jagdish S.

PARTICULARS OF CONTRIBUTORS:

1. Assistant Professor, Department of pathology, M.S. Ramaiah Medical College, Bangalore.
2. Senior Resident, Department of Pathology, Jawaharlal Institute of Postgraduate Medical Education and Research, Dhanvantri Nagar, Pondicherry.
3. Professor, Department of Pathology, Jawaharlal Institute of Postgraduate Medical Education and Research, Dhanvantri Nagar, Pondicherry.
4. Senior Resident, Department of Pathology, Jawaharlal Institute of Postgraduate Medical Education and Research, Dhanvantri Nagar, Pondicherry.

NAME, ADDRESS, E-MAIL ID OF THE CORRESPONDING AUTHOR:

Dr. Clement Wilfred Devadoss
No 76 A, First main road, John Bull Street, Viveknagar post ,
Bangalore 560047,Karnataka.
Phone: 9945226314
E-mail: clement.wilfred@yahoo.com

FINANCIAL OR OTHER COMPETING INTERESTS:

None.

Date of Submission: **May 12, 2012**
Date of Peer Review: **May 28, 2012**
Date of Acceptance: **Jun 27, 2012**
Date of Publishing: **Aug 10, 2012**